

# Coding for Hemodialysis Procedures

September 2020

**Jennifer Bash, RHIA, CIRCC, RCCIR, CPC, RCC**

*Director of Coding Education*

# Agenda

- Introduction
- Definitions
- Anatomy
- Presenting Problems for Hemodialysis
- General Coding Guidelines
- Procedures & Cases

# Disclaimer

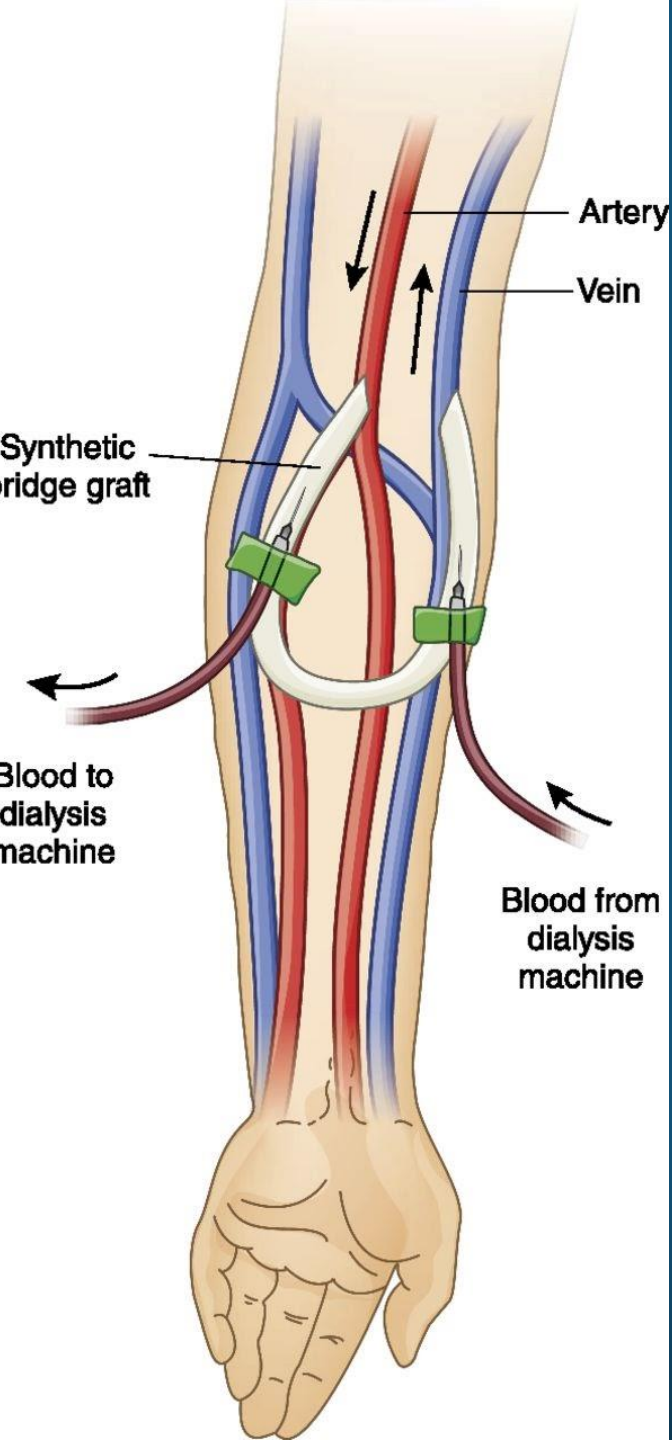
The information presented is based on the experience and interpretation of the presenters. Though all of the information has been carefully researched and checked for accuracy and completeness, ADVOCATE does not accept any responsibility or liability with regard to errors, omissions, misuse or misinterpretation.

CPT codes are trademark and copyright of the American Medical Association.

# Resources

- AMA
- CMS
- ACR/SIR
- ZHealth Publishing





# Hemodialysis Access Procedures

# Definitions

- **HEMODIALYSIS:** A method by which toxins are removed from the blood stream. Blood must be removed from the body, run through a dialysis machine, and returned to the body.
- **ANASTOMOSIS:** Surgical connection between two structures (e.g. vessels)
- **AV FISTULA:** Surgical connection between native artery and vein (autogenous)
- **AV GRAFT:** Surgical connection between artery and vein using a synthetic tube
- Autogenous is first choice
  - Longevity
  - Lower maintenance
  - Less risk of infection
- The goal with AV fistula/graft is to direct blood from an artery to a vein to allow increased blood flow for hemodialysis.

# Anatomy

## DIALYSIS CIRCUIT

Arterial anastomosis and adjacent artery through the entire outflow, including the IVC or SVC

## PERIPHERAL DIALYSIS SEGMENT

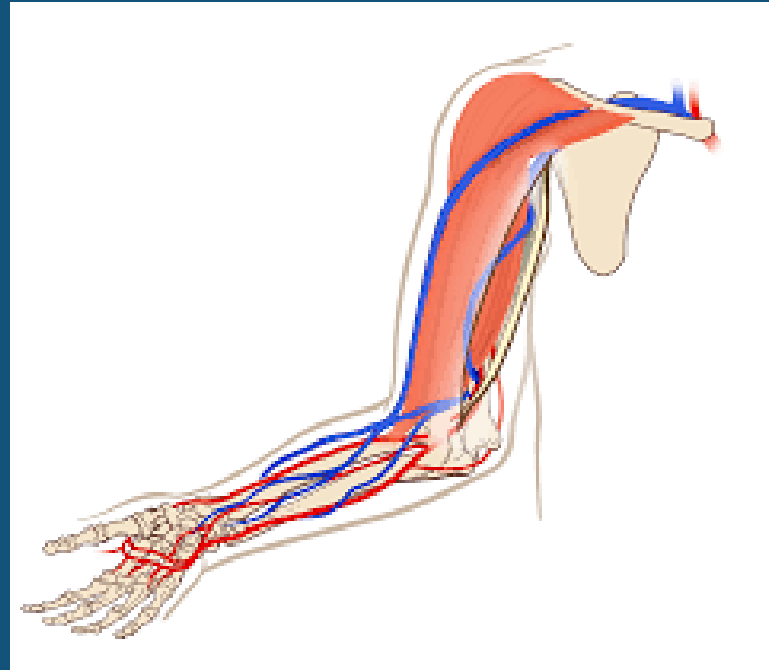
Upper Extremity: Extends through the axillary vein (or entire cephalic vein if cephalic outflow)

Lower Extremity: Extends through the common femoral vein

## CENTRAL DIALYSIS SEGMENT

Upper Extremity: Veins central to the axillary and cephalic veins including the subclavian and innominate veins through the vena cava

Lower Extremity: Veins central to the common femoral vein, including the external iliac and common iliac veins through the IVC





# Presenting Problems

## Complications of Fistula:

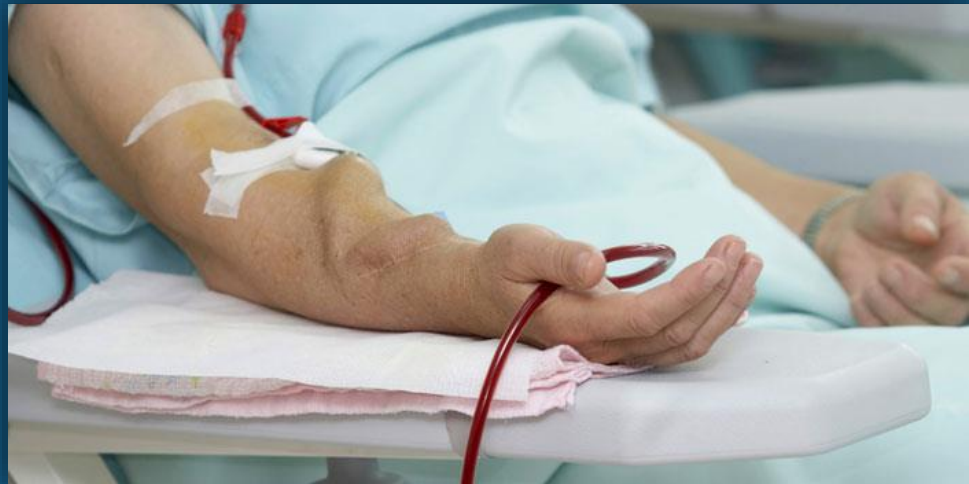- Stenosis
- Occlusion
- Blockage
- Thrombosis
- Rupture
- Dissection

## Presenting Problems:

- Abnormal pressures
- Prolonged bleeding
- Inefficient dialysis
- Extremity swelling
- Collateral channels of flow
- Steal syndrome

# Hemodialysis Procedures

- Fistulagram
- Thrombectomy
- Thrombolysis
- Angioplasty
- Stent
- Embolization



# Hemodialysis Access Maintenance Codes

CODE	DESCRIPTION
36901	AV shuntogram
36902	AV shuntogram and angioplasty of peripheral dialysis segment
36903	AV shuntogram, stent placement, and angioplasty of peripheral dialysis segment
36904	AV shuntogram and percutaneous mechanical thrombectomy
36905	AV shuntogram, angioplasty, and percutaneous mechanical thrombectomy
36906	AV shuntogram, stent placement, angioplasty, and percutaneous mechanical thrombectomy
+36907	Angioplasty of central dialysis segment (add-on)
+36908	Stent placement and angioplasty of central dialysis segment (add-on)
+36909	Embolization, main circuit or accessory veins

# AV Dialysis Access Coding Guidelines

- Percutaneous
- Comprehensive/Hierarchy
- All codes are unilateral and reported only once per encounter

INCLUDED	SEPARATELY CODED
ALL access/punctures into the graft	Ultrasound guidance
Imaging of the arterial inflow, the fistula/graft itself, the venous outflow, and central venography up to the level of the right atrium;	Moderate sedation
Imaging of the extremity distal and proximal to the fistula	Catheter advancement/imaging beyond peri-anastomotic segment to native artery
Imaging of the SVC is included when the fistulagram is performed in the upper extremity	PTA/Stent placement in native arteries distinct from peri-anastomotic region
Imaging of the IVC is included when the fistulagram is performed in the lower extremity	Overnight TPA infusion (rare)
Catheter advancements, including collaterals and to the vena cava	

# Case Study #1

Examination: IR FISTULAGRAM

Diagnosis/REASON FOR EXAM: Arteriovenous fistula stenosis, initial encounter

Additional History: no sedation, patent rt arm fistula

Contrast: 45 cc's omnipaque

mGy: 299.1 mGy

Fluoroscopy Time: 1.3 min minutes.

Fluoroscopy images: 3 + images obtained.

Conscious Sedation: No sedation was used. Pulse oximetry, heart rate, blood pressure, and vital signs were continuously monitored by an independent trained observer present.

Antibiotics such as first or second generation cephalosporin not given specifically for this procedure as not indicated/not necessary under the patient's current clinical status.

Technique: The risks, benefits and alternatives were discussed and informed consent was obtained. Prior to beginning the procedure, a formal time out was used to confirm the patient's identity and planned procedure.

Maximum sterile barriers including cap, mask, hand hygiene, sterile gloves, sterile gown, large sterile drape and 2% chlorhexidine for cutaneous antisepsis were used.

The skin about the right upper extremity fistula was sterilely prepped and draped. 1% lidocaine was instilled to achieve local anesthesia. Under direct sonographic guidance, a 21-gauge micropuncture needle was advanced into the left forearm fistula. An image of a patent vessel was recorded. The needle was exchanged over a microwire for a 5 French micropuncture transition dilator. Inner stylet and guidewire were removed.

Digital subtraction venograms of the venous outflow and central venous system was performed. Digital subtraction imaging of the arterial anastomosis was also done.

The sheath was removed and hemostasis achieved with manual compression. A sterile bandage was applied.

Complications: None.

Estimated blood loss: Minimal.

DISCUSSION:

Right upper extremity fistulogram demonstrates brachial artery to basilic vein AV fistula. Brisk outflow was seen during fistulagram. No significant competitive outflow veins were seen. No stenoses were seen. The anastomosis and central veins are patent.

IMPRESSION:

Patent right upper extremity brachial artery to basilic vein AV fistula.

Plan: This fistula is ready for immediate use.

# Case Study #1 Codes

- 36901: Introduction of needle(s) and/or catheter(s), dialysis circuit, with diagnostic angiography of the dialysis circuit, including all direct puncture(s) and catheter placement(s), injection(s) of contrast, all necessary imaging from the arterial anastomosis and adjacent artery through entire venous outflow including the inferior or superior vena cava, fluoroscopic guidance, radiological supervision and interpretation and image documentation and report
- 76937: Vascular US guidance

# Case Study #2



Procedure Note:

History: End-stage renal disease. Decreased left upper extremity AV fistula function. Right upper extremity AV fistula elevated venous pressures.

Exam: Fistulogram. Fistula dialysis circuit venoplasty.

The procedure as well as the benefits and risks, including bleeding, infection and vessel injury were explained to the patient or patient's guardian, who understood and wished to continue, and verbal and written informed consent was freely given, witnessed and placed on the patient's chart. Time out was performed with conformation of patient, procedure, site and side.

Monitoring: Continuous monitoring of oxygen saturation and heart rate as well as blood pressure every 5 minutes throughout the procedure.

The patient prepped draped usual sterile fashion following local anesthesia of the shunt was accessed with a micropuncture technique toward the venous anastomosis. Tract was dilated and a 6-French sheath was advanced toward the venous sides of the shunt. Shuntogram was performed demonstrating high-grade greater than 75% stenosis of the cephalic vein near the cephalic vein origin within vascular stents. The segmental stenosis was venoplasty to 8 mm diameter with 8 mm x 6 cm high pressure balloon with mild recoil narrowing post venoplasty. Central venogram demonstrated widely patent left axillary vein, left brachiocephalic vein and SVC. There is good inflow into the shunt loop. The catheters were removed and hemostasis was obtained with direct pressure. There was no adverse reaction or complication. The patient received 35 mL of Omni 240 for this procedure. The patient received 0.5 mg Versed and 25 mcg Fentanyl IV in divided doses for conscious sedation. A certified registered nurse independently monitored the patient and documented the sedation throughout the procedure. Moderate sedation was administered under the radiologist supervision for 20 minutes. 1.5 mg Versed and 75 mcg Fentanyl wasted postprocedure.

Total fluoro time: Two minutes and 44 seconds. 28 fluoroscopic images obtained.

Cefazolin/cefuroxime was not ordered for antimicrobial prophylaxis because the physician does not feel that the antibiotic treatment is warranted for this case for this patient. The physician feels that the patient is at very low risk for Venous Thromboembolism and therefore VTE prophylaxis was not warranted.

Impression: Right upper extremity AV fistulogram as described above. Venoplasty of a high-grade segmental stenosis at the cephalic vein origin within vascular stents up to 8 mm diameter with mild recoil narrowing and improved flow through the fistula postprocedure.

# Case Study #2 Codes

- 36902: Introduction of needle(s) and/or catheter(s), dialysis circuit, with diagnostic angiography of the dialysis circuit, including all direct puncture(s) and catheter placement(s), injection(s) of contrast, all necessary imaging from the arterial anastomosis and adjacent artery through entire venous outflow including the inferior or superior vena cava, fluoroscopic guidance, radiological supervision and interpretation and image documentation and report; with transluminal balloon angioplasty, peripheral dialysis segment, including all imaging and radiological supervision and interpretation necessary to perform the angioplasty
- 99152: Moderate sedation, initial 15 minutes

# Case Study #3

Procedure: Dialysis Lue Fistulagram

CLINICAL HISTORY: 2, N, ESRD, END STAGE RENAL DISEASE BARD ATLAS 12X40 BARD FLUENCY STENT GRAFT 13.5X60

Comparison: None.

Intraprocedure medications: 4000 units of heparin 2 mg of Versed 100 mcg of fentanyl  
Moderate sedation was performed.

The physician spent 45 minutes of face to face sedation time with the patient. The radiology nurse monitored the cardiorespiratory function of the patient.

FLUORO TIME: 4:20 (MIN:SEC)

Total Number of Images is 136. Consent: Obtained from the patient prior to the procedure. All risks and benefits were explained and patient allowed to ask questions

Procedure: All elements of maximal sterile barrier technique followed including: cap and mask and sterile gown and sterile gloves and a large sterile sheet and hand hygiene and 2% chlorhexidine for cutaneous antiseptis. Sterile ultrasound covers and sterile ultrasound jelly were used for any ultrasound guided component. The fistula was punctured

going towards the outflow portion of the vein in the area of previously known stenosis. 5 French dilator was placed and fistulogram performed. Focal greater than 80% diameter stenosis in the outflow vein is again identified. This lesion is crossed with a Glidewire. A 7 French sheath was then placed. Balloon angioplasty performed with a 10 mm 12 mm balloon. After balloon angioplasty there is some contrast extravasation outside the expected vein. The vein is irregular in its margin. At this point I placed a 10 French sheath in the fistula and a fluency stent graft 13.5 mm x 60 mm was deployed across the area of irregularity. Post dilatation with 12 mm balloon performed.

Follow-up imaging demonstrated no significant residual stenosis. The distal aspect of the stent graft is slightly irregular. If the fistula does not puncture clots off again this stent graft may need to be extended

Radiographic findings: High-grade outflow vein stenosis and a large vessel otherwise balloon angioplastied with a 10 12 mm balloon and contrast extravasation noted. Stent graft placed good flow through the stent graft noted at the conclusion of the stent graft placement. Sheath removed.

Complications: none

Impression: Fistulogram as described. Requiring stent graft placement in the outflow portion of the fistula

# Case Study #3 Codes

- 36903: Introduction of needle(s) and/or catheter(s), dialysis circuit, with diagnostic angiography of the dialysis circuit, including all direct puncture(s) and catheter placement(s), injection(s) of contrast, all necessary imaging from the arterial anastomosis and adjacent artery through entire venous outflow including the inferior or superior vena cava, fluoroscopic guidance, radiological supervision and interpretation and image documentation and report; with transcatheter placement of intravascular stent(s), peripheral dialysis segment, including all imaging and radiological supervision and interpretation necessary to perform the stenting, and all angioplasty within the peripheral dialysis segment
- 99152: Moderate sedation, initial 15 minutes

# Case Study #4

CLINICAL HISTORY: 50 years and 9 months year-old F with a **clotted left arm dialysis graft**.  
PROCEDURES: Declot left arm dialysis graft.

CONSENT: Informed consent was obtained from the patient after an explanation of risks, benefits and alternatives. The risks were explained to include bleeding, damage to the graft, infection of the graft, damage to blood vessels where the balloon is inflated, blockage of blood vessels in the arm or lungs by blood clots, contrast reaction, and interference with heart beat, blood pressure, or breathing related to the sedation.  
SEDATION: **Moderate sedation** was administered using Versed and Fentanyl. The patient was continuously monitored during the procedure by a nurse using automated blood pressure, EKG, and pulse oximetry measurements. The **intra-service time was 52 minutes**

TECHNIQUE: The patient's left upper extremity was evaluated with ultrasound in the holding area and there was blood flow to the mid fistula but then thrombus was noted in the mid fistula and as it continued to the outflow and became occlusive. Using a 25 gauge needle 2 milligrams of tPA and 3000 units of heparin were given into the **thrombus within the fistula while in the holding area**. The patient was placed supine on the fluoroscopy table. Using sterile technique and local anesthesia with **ultrasound guidance, the graft was punctured** through a small skin incision. Continuous real time ultrasound monitoring of the puncture needle entry into the graft was performed and documented. Under fluoroscopic guidance, a wire was passed centrally. A 5 F dilator was passed over the wire. The wire was exchanged for a stiff angled glide wire. The dilator was exchanged for a 6 F sheath. A small amount of contrast was injected to **confirm thrombosis of the graft. Clot was aspirated through the sheath and mechanical thrombectomy was performed**. A 7 mm balloon was advanced over a wire and dilated throughout the fistula and into the central veins. Following this an angiogram was performed which demonstrated flow through the fistula. Exchange was made for an 8 millimeter balloon which was used to further dilate the fistula, outflow vein, and stent in the outflow vein. Following this an angiogram was performed which demonstrated good flow through the fistula.

CONTRAST: 46 ml Visipaque 320.

FLUOROSCOPY DOSE: 144 mGy KAP.

FINDINGS: Initially the graft was partially filled with clot. After chemical and mechanical thrombectomy the graft was patent, with flow. The patient has tiny emboli in the digital arteries of the 2nd through 5th fingers. The thumb is well perfused. The brachial, radial, ulnar, and interosseous arteries are widely patent. AV shuntogram demonstrates that the arterial anastomosis is to the brachial artery. The arterial inflow to the graft demonstrates a moderate stenosis.

IMPRESSION: 1. Tiny emboli to the left 2nd through 5th fingers. Doctor early was contacted and came to see the patient and review the images. The patient was admitted to the ICU and placed on a heparin drip. 2. Successful declog of the left arm dialysis graft. If the graft should thrombose again, it would be amenable to percutaneous revascularization.

# Case Study #4 Codes

- 36904: Percutaneous transluminal mechanical thrombectomy and/or infusion for thrombolysis, dialysis circuit, any method, including all imaging and radiological supervision and interpretation, diagnostic angiography, fluoroscopic guidance, catheter placement(s), and intraprocedural pharmacological thrombolytic injection(s)
- 76937-Vascular US guidance
- 99152: Moderate sedation, initial 15 minutes



# Case Study #5

Procedure:

1. Thrombectomy of left AV graft with Treratola catheter and 4 mg of TPA and IV heparin.
2. Drug coated balloon angioplasty and balloon angioplasty of mid graft stenosis.
3. Balloon angioplasty of venous anastomosis stenosis.
4. Bidirectional access.

Pre-operative diagnosis: Thrombosed AV graft

Venous anastomosis stenosis. Intragraft stenosis.

Post-operative diagnosis: ESRD

Estimated blood loss: 5 cc

Complications: None

TECHNIQUE: Informed consent obtained after discussion of all risks and benefits. All questions answered.

Cephalosporin and Cefuroxime was not ordered for antimicrobial prophylaxis due to medical standard of care requiring skin prep and no placement of long-term indwelling stent or catheter. VTE prophylaxis was not ordered or administered and not indicated due to normal unrestricted ambulation of the patient both before and after the procedure. Maximum sterile barrier technique was utilized. 4000 units of heparin given IV. Mechanical thrombectomy of a thrombosed left upper extremity AV graft was performed by puncturing the graft with two 18g needles in opposing orientation and placing two crossed 6-French sheaths over 0.035 wires. First the thrombus was laced with 4 mg of TPA in 50 cc of normal saline via the Treratola catheter. The Treratola catheter was used to perform a mechanical embolectomy via both sheaths. Following this, angioplasty of a greater than 50% hemodynamically significant stenosis at the mid body of the graft was treated with 8 mm balloon drug coated paclitaxel preceded by conventional balloon angioplasty.. The arterial plug was removed with a Fogarty balloon catheter. Following the procedure, a pulse returned to the graft.

All catheters and wires removed. Hemostasis obtained with a pursestring sutures. Sterile dressings applied. No immediate complications.

Radiation exposure in Reference air Kerma:21 mGy Total image #: 13

Fluoroscopy time: 3. Minutes

Impression:

1. Mechanical and pharmacological thrombolysis/thrombectomy of the left upper extremity AV graft.
2. Drug coated balloon angioplasty treatment of intragraft stenosis..

# Case Study #5 Codes

- 36905: Percutaneous transluminal mechanical thrombectomy and/or infusion for thrombolysis, dialysis circuit, any method, including all imaging and radiological supervision and interpretation, diagnostic angiography, fluoroscopic guidance, catheter placement(s), and intraprocedural pharmacological thrombolytic injection(s); with transluminal balloon angioplasty, peripheral dialysis segment, including all imaging and radiological supervision and interpretation necessary to perform the angioplasty

# Case Study #6

Procedure(s): IR Declot w/Angioplasty/Stent

HISTORY: End stage renal disease with clotted AV access.

ASA CODE: 3

CONSENT: Informed consent was obtained prior to the start of the procedure. The patient and/or representatives were given ample opportunity to ask questions regarding the procedure.

PROCEDURE: A time-out was performed and documented prior to the start of the procedure. The patient was sterilely prepped and draped and placed in the supine position on the angiographic table. Under direct ultrasound guidance, a needle was introduced into the hemodialysis access in the venous direction. Still ultrasound images were saved for the patient's archive. An area of hemodynamically significant stenosis was treated with venous angioplasty and follow-up imaging demonstrated that this stenosis was resistant to an angioplasty with residual hemodynamically significant stenosis, that was treated with a covered stent. Thrombectomy was performed. Follow-up imaging was done and the procedure was ended. Sterile dry dressings were applied over the puncture sites, which were closed with suture.

RADIOGRAPHIC INTERPRETATION: Initial angiogram images demonstrate an area of hemodynamically significant stenosis on the venous limb of the hemodialysis fistula. This was resistant to initial angioplasty and follow-up imaging demonstrates residual stenosis, which is hemodynamically significant. This was treated with a covered stent. There is an improvement in luminal diameter and flow dynamics on follow-up imaging. A still ultrasound image was saved for the patient's archive demonstrating satisfactory needle position for initial access.

COMPLICATIONS: None

ESTIMATED BLOOD LOSS: Less than 5 mls

MEDICATION USED: 2 mls of 1% subcutaneous Lidocaine; 2 mg of IV Versed; 50 mcg of IV Fentanyl SEDATION TIME: 43 minutes. Under physician supervision, drug(s) were administered intravenously for moderate sedation. Pulse oximetry, heart rate, and BP are continuously monitored with an independent trained observer present. The physician spent 30 minutes of face to face sedation time with the patient.

Venous thromboembolism prophylaxis was not indicated on this patient following the procedure because they were ambulatory.

IMPRESSION:

Technically successful thrombectomy with anterior and venous angioplasty.

# Case Study #6 Codes

- 36906: Percutaneous transluminal mechanical thrombectomy and/or infusion for thrombolysis, dialysis circuit, any method, including all imaging and radiological supervision and interpretation, diagnostic angiography, fluoroscopic guidance, catheter placement(s), and intraprocedural pharmacological thrombolytic injection(s); with transcatheter placement of intravascular stent(s), peripheral dialysis segment, including all imaging and radiological supervision and interpretation necessary to perform the stenting, and all angioplasty within the peripheral dialysis circuit
- 76937-Vascular US guidance
- 99152: Moderate sedation, initial 15 minutes

# Case Study #7

Procedure Note:

EXAM:

1. Diagnostic fistulogram.

2. Venous angioplasty.

Preoperative Diagnosis: End-stage renal disease, with dysfunctional fistula.

Postoperative Diagnosis: End-stage renal disease, with dysfunctional fistula.

Estimated Blood Loss: Less than 25 cc. FLUOROSCOPY TIME:

2.4 min: Air Kerma 65 mGy DAP 17242 mGycm<sup>2</sup> Cefazolin/ cefuroxime was not ordered for antimicrobial prophylaxis as it is not indicated or strongly backed by the medical literature.

SEDATION/ANESTHESIA: 1% lidocaine, local. The risks, benefits, and alternatives to the procedure were discussed in detail with the patient who gave verbal and written consent, which was then placed in the chart. Appropriate time-out was performed prior to the procedure. Additional DVT prophylaxis was not provided due to the short nature of the procedure, the lack of general anesthesia, and is not strongly backed by the medical literature for this patient population undergoing this type of minimally invasive image guided procedure. First or second generation cephalosporin was not ordered for antimicrobial prophylaxis as it is not indicated or strongly backed by the medical literature.

TECHNIQUE: All elements of maximal sterile barrier technique were met including cap, mask, sterile gown, sterile gloves, large sterile sheet, hand hygiene and 2% chlorhexidine for cutaneous antisepsis. Local anesthetic was administered. Using Seldinger technique and micropuncture access, a 4-French micro-introducer was advanced into the fistula over the wire and a fistulogram was performed. The access was then converted to a 7 French sheath and a stiff Glidewire directed centrally into the distal SVC. The high-grade stenosis in the distal subclavian vein was then angioplastied with a 10 x 40 mm Opta balloon with improvement in flow on post angioplasty angiography. The patient tolerated the procedure well. Following access removal, manual compression as well as a `Z` suture was applied for hemostasis.

FINDINGS: These images demonstrate high-grade short segment flow-limiting stenosis in the distal right subclavian vein, just proximal to the SVC confluence. Post angioplasty angiography densities improved flow through the stenotic segment. No flow-limiting stenosis in the arterial limb. Successful diagnostic cystogram with identification and treatment of high-grade stenosis in the distal right subclavian vein.



# Case Study #7 Codes

- 36901: Introduction of needle(s) and/or catheter(s), dialysis circuit, with diagnostic angiography of the dialysis circuit, including all direct puncture(s) and catheter placement(s), injection(s) of contrast, all necessary imaging from the arterial anastomosis and adjacent artery through entire venous outflow including the inferior or superior vena cava, fluoroscopic guidance, radiological supervision and interpretation and image documentation and report
- 36907+: Transluminal balloon angioplasty, central dialysis segment, performed through dialysis circuit, including all imaging and radiological supervision and interpretation required to perform the angioplasty (List separately in addition to code for primary procedure)

# Case Study #8

Procedure(s): IR Fistulagram w/Stent

HISTORY: End stage renal disease, fistula malfunction.

ASA CODE: 3

CONSENT: Informed consent was obtained prior to the start of the procedure. The patient and/or representatives were given ample opportunity to ask questions regarding the procedure.

PROCEDURE: A time-out was performed and documented prior to the start of the procedure. The patient was sterilely prepped and draped and placed in the supine position on the angiographic table. Under direct ultrasound guidance, a needle was introduced into the hemodialysis fistula in the venous direction. Still ultrasound images were saved for the patient's archive. A diagnostic fistulogram reveals hemodynamically significant central venous stenosis and stenosis within the venous limb of the fistula. This was resistant to initial angioplasty and a residual stenosis at both of these areas was treated with covered stent. Sterile dry dressings were applied over the puncture sites, which were closed with suture at the end of the procedure.

RADIOGRAPHIC INTERPRETATION: There are hemodynamically significant stenoses along the venous limb of the hemodialysis fistula and within the central venous outflow including the subclavian left and brachiocephalic veins. Resistant stenosis was noted after initial angioplasty and these areas following stent placement. These areas improved in luminal diameter and flow dynamics.

COMPLICATIONS: None

ESTIMATED BLOOD LOSS: < 5 mls

MEDICATION USED:

1] mls of 1% subcutaneous Lidocaine

3 mg of IV Versed

75 mcg of IV Fentanyl

SEDATION TIME: 43 minutes. Under physician supervision, drug(s) were administered intravenously for moderate sedation. Pulse oximetry, heart rate, and BP are continuously monitored with an independent trained observer present. The physician spent 30 minutes of face to face sedation time with the patient.

Venous thromboembolism prophylaxis was not indicated on this patient following the procedure because they were ambulatory.

IMPRESSION:

Technically successful hemodialysis fistulogram with central venous and venous angioplasty and stent placement.

# Case Study #8 Codes

- 36903: Introduction of needle(s) and/or catheter(s), dialysis circuit, with diagnostic angiography of the dialysis circuit, including all direct puncture(s) and catheter placement(s), injection(s) of contrast, all necessary imaging from the arterial anastomosis and adjacent artery through entire venous outflow including the inferior or superior vena cava, fluoroscopic guidance, radiological supervision and interpretation and image documentation and report; with transcatheter placement of intravascular stent(s), peripheral dialysis segment, including all imaging and radiological supervision and interpretation necessary to perform the stenting, and all angioplasty within the peripheral dialysis segment
- 36908+: Transcatheter placement of intravascular stent(s), central dialysis segment, performed through dialysis circuit, including all imaging and radiological supervision and interpretation required to perform the stenting, and all angioplasty in the central dialysis segment (List separately in addition to code for primary procedure)
- 76937-Vascular US guidance
- 99152: Moderate sedation, initial 15 minutes

# Case Study #9

Procedure(s): IR Fistulagram

HISTORY: End stage renal disease. Fistula malfunction. Vascular steal from large venous collaterals.

CONSENT: Informed consent was obtained prior to the start of the procedure. The patient and/or representatives were given ample opportunity to ask questions regarding the procedure.

PROCEDURE: A time-out was performed and documented prior to the start of the procedure. The patient was sterilely prepped and draped and placed in the supine position on the angiographic table. Under direct ultrasound guidance, a needle was introduced into the hemodialysis fistula in the arterial direction. Diagnostic fistulagram was performed. Selection of individual large collateral veins was performed with catheter and wire and these were embolized with tornado embolic coils. Repeat angiogram was done. The decision was then made to end the procedure at this time.

RADIOGRAPHIC INTERPRETATION: Large venous collaterals are noted to produce vascular steal from the main channel hemodialysis fistula which improves following embolization with improvement in flow dynamics. Still ultrasound images were saved during this procedure for vascular access to the patient's archive.

COMPLICATIONS: None

ESTIMATED BLOOD LOSS: < 5 mls

MEDICATION USED:

1 mls of 1% subcutaneous Lidocaine

2 mg of IV Versed

50 mcg of IV Fentanyl

24 mls of Isovue

SEDATION TIME: 23 minutes. Under physician supervision, drug(s) were administered intravenously for moderate sedation. Pulse oximetry, heart rate, and BP are continuously monitored with an independent trained observer present. The physician spent 30 minutes of face to face sedation time with the patient.

Venous thromboembolism prophylaxis was not indicated on this patient following the procedure because they were ambulatory.

IMPRESSION:

Technically successful hemodialysis Fistulogram with embolization as detailed above.

# Case Study #9 Codes

- 36901: Introduction of needle(s) and/or catheter(s), dialysis circuit, with diagnostic angiography of the dialysis circuit, including all direct puncture(s) and catheter placement(s), injection(s) of contrast, all necessary imaging from the arterial anastomosis and adjacent artery through entire venous outflow including the inferior or superior vena cava, fluoroscopic guidance, radiological supervision and interpretation and image documentation and report
- 36909+: Dialysis circuit permanent vascular embolization or occlusion (including main circuit or any accessory veins), endovascular, including all imaging and radiological supervision and interpretation necessary to complete the intervention (List separately in addition to code for primary procedure)
- 76937-Vascular US guidance
- 99152: Moderate sedation, initial 15 minutes

# Q&A





# Thank you!

Jennifer Bash, RHIA, CIRCC, RCCIR, CPC, RCC  
Director of Coding Education

ADVOCATE Revenue Cycle Management  
5475 Rings Road, Suite 300 | Dublin, Ohio 43017  
O: 614.210.1885 | F: 614.210.1874  
[jennifer.bash@advocatercm.com](mailto:jennifer.bash@advocatercm.com) | [www.radadvocate.com](http://www.radadvocate.com)

